

CORRELATION OF SALINE INFUSION SONOGRAPHY AND HYSTEROSCOPY FOR CAVITY EVALUATION BEFORE IVF

S. Shanmugavalli¹, V.Radha², Monna Pandurangi³, N.Sanjeeva Reddy⁴

Received : 24/04/2024
Received in revised form : 11/06/2024
Accepted : 28/06/2024

Keywords:

Saline infusion sonography, hysteroscopy, cavity evaluation, in vitro fertilization (IVF), endometrial polyp, uterine anomalies, difficult cannulation.

Corresponding Author:

Dr. S. Shanmugavalli,
Email: shannanthu@gmail.com

DOI: 10.47009/jamp.2024.6.3.200

Source of Support: Nil,
Conflict of Interest: None declared

Int J Acad Med Pharm
2024; 6 (3); 901-905



¹Fellow in Reproductive Medicine, Department of Reproductive Medicine and Surgery, Sri Ramachandra Medical College and Research Institute, Tamilnadu, India.

²Professor, Department of Reproductive Medicine and Surgery, Sri Ramachandra Medical College and Research Institute, Tamilnadu, India.

³Associate Professor, Department of Reproductive Medicine and Surgery, Sri Ramachandra Medical College and Research Institute, Tamilnadu, India.

⁴Professor, Department of Reproductive Medicine and Surgery, Sri Ramachandra Medical College and Research Institute, Tamilnadu, India.

Abstract

Background: Accurate assessment of the uterine cavity before in vitro fertilisation (IVF) is crucial because of its impact on fertility outcomes. Saline infusion sonography (SIS) provides real-time imaging and is minimally invasive, whereas hysteroscopy is preferred for direct visualisation. This study aimed to correlate the efficacy of SIS (2D) with hysteroscopy in the diagnosis of intrauterine pathologies before IVF. **Material and Methods:** This retrospective study was conducted at the Sri Ramachandra Institute of Higher Education and Research, Chennai, from December 2018 to December 2021 on 100 infertile women diagnosed with AIS who underwent SIS (2D) followed by hysteroscopy. Data including demographic details, medical history, and clinical findings from SIS (2D) and hysteroscopy were extracted from each patient's medical records. **Results:** The average duration of infertility was 6.5 ± 4 years, and the mean endometrial thickness was 5.9 ± 2.1 mm. Among them, 74% had primary infertility, and 26% had secondary infertility. Using SIS (2D) and hysteroscopy, the abnormalities detected included polyps (9% vs. 18%), uterine anomalies (4% vs. 12%), and adhesions (0% vs. 9%). SIS (2D) showed a sensitivity of 26.5% and specificity of 100% for cavity evaluation ($p = 0.022$), whereas it demonstrated a sensitivity of 38.9% and specificity of 97.6% for polyp detection ($p = 0.016$). The detection of uterine anomalies and cannulation were not significantly different ($p = 0.062$ and $p = 0.345$, respectively). **Conclusion:** SIS (2D) is a less invasive option than hysteroscopy for diagnosing intrauterine pathologies such as polyps and uterine anomalies before IVF.

INTRODUCTION

Uterine cavity abnormalities are a cause of infertility in approximately 10%-15% of women. In women with recurrent implantation failure, abnormalities are found in up to 50% of women.^[1,2] Thus, accurate evaluation of the uterine cavity is pivotal in the management of infertility, as the most critical step for a successful in vitro fertilisation (IVF) outcome is embryo implantation, which is influenced by a positive cross-talk between an adequate quality embryo and a receptive endometrium. Moreover, intrauterine abnormalities, such as polyps, fibroids, and adhesions, can significantly affect the success of fertility treatment. Therefore, diagnosing and treating these abnormalities is recommended, as their surgical correction may potentially enhance the

chances of conception and a successful pregnancy.^[2,3]

Saline infusion sonography (SIS) is a diagnostic technique known for its efficiency and cost-effectiveness, offering quicker procedures than hysteroscopy. Although hysteroscopy remains the gold standard for direct visualisation and immediate treatment of uterine cavity issues, it is invasive and costly, with associated discomfort and risks. Reports on the diagnostic accuracy of SIS vary, with some considering it sufficient for diagnosing normal uterine cavities while others suggest limitations.^[2-6] Despite the established role of hysteroscopy in high-resolution imaging, SIS has emerged as a preferred, less invasive option for real-time visualisation and the effective detection of abnormalities in clinical settings. Establishing a correlation between SIS

findings and hysteroscopy is crucial for enhancing pre-IVF assessments, informing clinical decisions, and potentially improving outcomes in assisted reproduction.^[3,7] Thus, the present study correlated the efficacy of SIS (2D) with hysteroscopy in the diagnosis of intrauterine pathologies before IVF.

MATERIALS AND METHODS

This retrospective study included 100 women with infertility diagnosed with AIS in the Department of Reproductive Medicine and Surgery, Sri Ramachandra Institute of Higher Education and Research, Chennai, from December 2018 to December 2021.

Inclusion Criteria

Women aged 18–50 years, infertile women undergoing SIS (2D) followed by hysteroscopy for cavity evaluation before IVF, and patients diagnosed with Assisted Infertility Services (AIS) were included.

Exclusion Criteria

Patients with incomplete medical records and those with other significant medical conditions that could affect fertility or the outcomes of SIS (2D) and hysteroscopy were excluded.

Methods and data collection process

The study included patients who underwent FET cycles and consented to a review of their medical records. Each patient's medical records were screened, and data were collected, including demographic details (age, body mass index), past medical history, baseline parameters, and clinical findings obtained through SIS (2D) and hysteroscopy.

Statistical Analysis

Data were collected and analysed using IBM SPSS Statistics for Windows, Version 23.0 (Armonk, IBM Corp). Continuous variables are expressed as mean and standard deviation, and categorical variables are summarised as frequencies and percentages. To evaluate the efficacy of SIS (2D) compared with hysteroscopy, a receiver operating characteristic (ROC) curve was plotted, and the sensitivity, specificity, PPV, and NPV were calculated. Statistical significance was set at $p \leq 0.05$.

RESULTS

The study participants had a mean age of 31.1 ± 4.7 years and a mean BMI of 26.5 ± 4.5 kg/m². The average duration of infertility among the participants was 6.5 ± 4 years, and the mean endometrial thickness was measured at 5.9 ± 2.1 mm. Regarding the type of infertility, 74% of the participants had primary infertility and 26% had secondary infertility. [Table 1]

We detected abnormalities using SIS (2D) and hysteroscopy methods. Polyps were found in 9% of cases with SIS (2D) and 18% with hysteroscopy. Uterine anomalies were detected in 4% of SIS (2D)

cases and 12% of hysteroscopy cases. Adhesions were not detected using SIS (2D) but were found in 9% of cases with hysteroscopy. Chronic endometritis was also not detected with SIS (2D) but was identified in 10% of cases with hysteroscopy. Difficult cannulation occurred in 15% of the cases using SIS (2D) and in 19% of the cases using hysteroscopy. [Table 2]

The sensitivity of SIS (2D) for cavity evaluation compared with hysteroscopy was 26.5%, while its specificity was 100%. The positive predictive value (PPV) of SIS (2D) was 100%, whereas the negative predictive value (NPV) was 58.6%. The comparison between SIS (2D) and hysteroscopy showed a statistically significant difference, with a p-value of 0.022. [Table 3 and Figure 1]

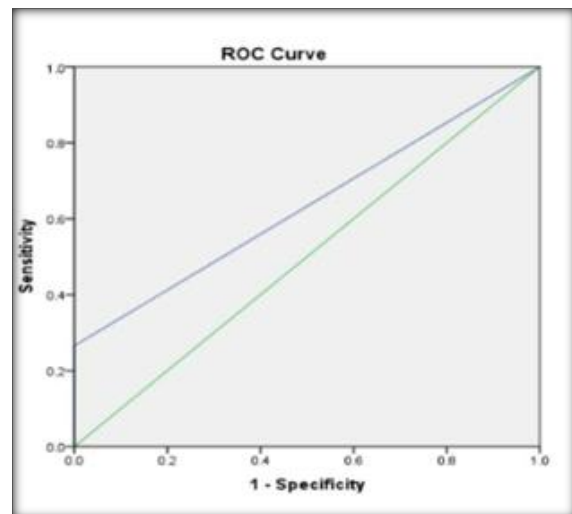


Figure 1: ROC Curve for Cavity Evaluation - SIS (2D) vs. Hysteroscopy

The sensitivity of SIS (2D) for the detection of polyps compared with hysteroscopy was 38.9%, while its specificity was 97.6%. The positive predictive value (PPV) of the SIS (2D) was 77.8%, while the negative predictive value (NPV) was 87.9%. The comparison showed a statistically significant difference with a p-value of 0.016. [Table 4 and Figure 2]

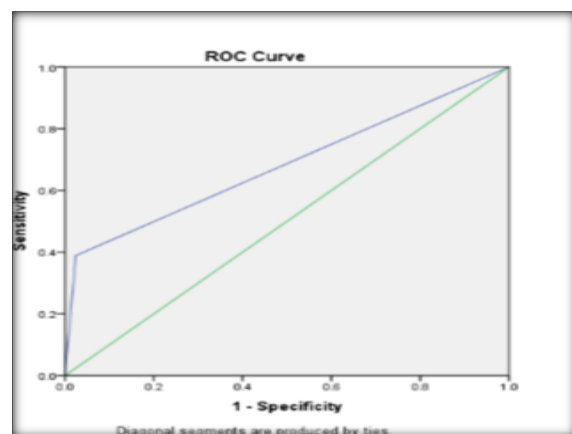


Figure 2: ROC curve for detection of polyps

The sensitivity of SIS (2D) for the detection of uterine anomalies compared with hysteroscopy was 33.3%, while its specificity was 100%. The positive predictive value (PPV) of SIS (2D) was 100%, whereas the negative predictive value (NPV) was 91.7%. The comparison showed a statistically insignificant difference, with a p-value of 0.062. [Table 5 and Figure 3]

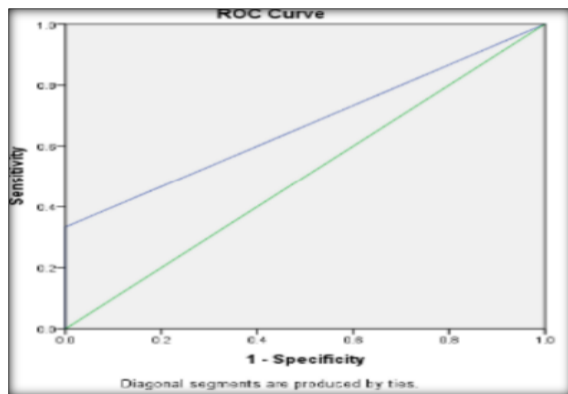


Figure 3: ROC curve for detection of uterine anomaly

The sensitivity of SIS (2D) for the detection of Difficult Cannulation compared with hysteroscopy

was 26.3%, while its specificity was 87.7%. The positive predictive value (PPV) of SIS (2D) was 33.3% and the negative predictive value (NPV) was 83.5%. The comparison showed a statistically non-significant difference with a p-value of 0.345. [Table 6 and Figure 4]

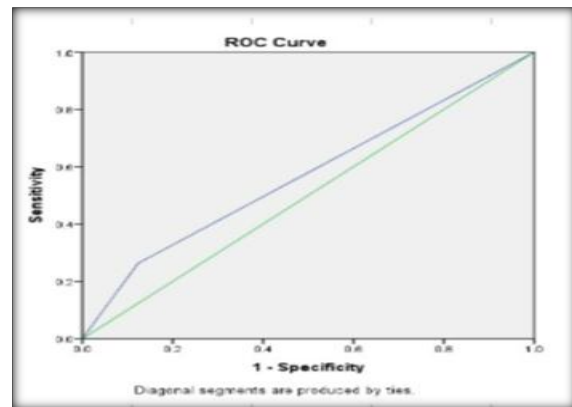


Figure 4: ROC curve for detection of difficult cannulation - SIS (2D) vs. hysteroscopy

Table 1: Demographic and clinical characteristics of the study participants

Variables	Mean ± SD
Age	31.1 ±4.7 years
BMI	26.5 ±4.5 kg/m2
Duration of infertility	6.5 ±4 years
Endometrial Thickness	5.9 ±2.1 mm
Type of infertility	Percentage
	Primary 74%
	Secondary 26%

Table 2: Distribution of studied cases

Abnormality	SIS (2D) (n=100)	Hysteroscopy (n=100)
Polyp	9(9%)	18(18%)
Uterine Anomaly	4(4%)	12(12%)
Adhesions	0(0%)	9(9%)
Chronic Endometritis	0(0%)	10(10%)
Difficult Cannulation	15(15%)	19(19%)

Table 3: Cavity evaluation - SIS (2D) vs. hysteroscopy

Sensitivity	26.5
Specificity	100
PPV	100
NPV	58.6

Table 4: Detection of polyp

Sensitivity	38.9
Specificity	97.6
PPV	77.8
NPV	87.9

Table 5: Detection of uterine anomaly

Sensitivity	38.9
Specificity	100
PPV	100
NPV	91.7

Table 6: Detection of difficult cannulation - SIS (2D) vs. hysteroscopy

Sensitivity	26.3
Specificity	87.7
PPV	33.3
NPV	83.5

DISCUSSION

In this study, the participants had a mean age of $31.1^{[1]} \pm 4.7$ years. Comparatively, Ndoua et al. reported a higher mean age of 39.3 ± 7.8 years in their study.^[2] In another study conducted by Chauhan and Singh in Uttar Pradesh, the majority of women with infertility were aged between 25-29 years (53.3%), followed by 20-24 years (18.3%) and 30-34 years (18.3%). The mean age reported in their study was 28.02 ± 4.18 years.^[7] We have reported that the mean BMI of participants was 26.5 ± 4.5 kg/m², whereas Ndoua et al. reported a mean BMI of 28.7 ± 4.1 .^[2]

The most common finding observed in both SIS and hysteroscopy was polyps, with 39% of polyps detected by hysteroscopy identified by SIS (2D). However, 22% of polyps detected by SIS (2D) were not confirmed by hysteroscopy. Despite a sensitivity of 38.8%, SIS (2D) exhibited a high specificity (97.6%), making it a reasonable tool for diagnosing polyps before IVF. Unicornuate uteri were effectively identified by SIS (2D); however, 66% of uterine anomalies, particularly small septae (< 1 cm), were missed by SIS (2D). Therefore, SIS (2D) is suitable for diagnosing uterine anomalies, except for small septae, prior to IVF.

Chauhan and Singh demonstrated that on hysteroscopy, 8.3% of patients had endometrial polyps, 8.3% had submucosal fibroids, 5% had septa, and 5% had adhesions. On SIS, 11.7% had endometrial polyps, 10% had submucosal fibroids, 10% had septa, and 5% had adhesions.^[7]

Abdelazim and Elezz reported uterine cavity abnormalities in 40.3% of patients before IVF/ICSI treatment: 17.7% had endometrial polyps, 10.5% had submucosal fibroids, 4.8% had uterine septa, 3.2% had uterine adhesions, 2.4% had endometrial hyperplasia, and 1.6% had thin or atrophic endometrium. Hysteroscopy demonstrated higher sensitivity (98.0% vs. 96.2%), specificity (100.0% vs. 98.7%), and accuracy (99.2% vs. 97.6%) compared to SIS for uterine cavity assessment before IVF/ICSI treatment. Hysteroscopy also showed superior positive predictive value (100% vs. 98%) and negative predictive value (98.7% vs. 97.4%) than SIS.^[3]

Tokgoz et al. identified intracavitary space-occupying lesions in 18.9% of cases, with endometrial polyps accounting for 17.4% and submucosal fibroids accounting for 1.5%. Among these, hysteroscopy confirmed 3 endometrial polyps, 4 submucosal fibroids, 3 septa, and 2 adhesions. SIS initially detected 10 cases as abnormal which were later found normal on hysteroscopy, and 4 cases as normal on SIS which were later identified as

abnormal on hysteroscopy.^[8] Furthermore, Pujar et al., conducted a study in Karnataka, India, revealing that in the evaluation of the uterine cavity, compared to hysteroscopy, SIS exhibited a sensitivity of 97.8%, specificity of 88.8%, a positive predictive value (PPV) of 97.8%, and a negative predictive value (NPV) of 88.8%.^[9]

Various studies conducted across different regions of India have reported a sensitivity of SIS for detecting abnormalities in the uterine cavity ranging from 80% to 100%, with a specificity ranging from 70% to 100%.^[10-13] Filmy adhesions and features of chronic endometritis are exclusively diagnosed by hysteroscopy, indicating that SIS (2D) is not suitable for detecting these conditions. Regarding cannulation difficulties, 66% of cases labelled as difficult in SIS (2D) were not challenging during hysteroscopy; conversely, 73% of cases with easy cannulation in SIS (2D) required dilation during hysteroscopy. Thus, not all patients experiencing difficult cannulation in SIS (2D) encountered the same issue during hysteroscopy and vice versa.

This study demonstrates that SIS is highly sensitive and specific for detecting intrauterine abnormalities in infertile women before IVF treatment compared to gold standard hysteroscopy. Further research is warranted to assess the diagnostic accuracy of these methods in larger populations and explore the feasibility of performing concurrent surgical procedures for treatable pathologies such as polyps.

CONCLUSION

In conclusion, SIS (2D) is a less invasive option than hysteroscopy for diagnosing intrauterine pathologies such as polyps and uterine anomalies before IVF, although it has limitations in accurately detecting intrauterine adhesions and chronic endometritis. It remains a viable alternative for cavity evaluation in resource-limited settings where 3D ultrasound and hysteroscopy may not be readily accessible.

REFERENCES

1. Pundir J, Toukhy E. Uterine cavity assessment prior to IVF. *Womens Health (Lond)* 2010; 6:847-8. <https://doi.org/10.2217/whe.10.61>.
2. Ndoua C, Belinga E, Ngah G, Metogo JN, Mendibi S, Kasia JM. Accuracy of saline infusion sonography versus hysteroscopy in the evaluation of uterine cavity abnormalities in infertile women at CHRACERH, Yaounde, Cameroon. *Int J Reprod* 2018; 7:4355-9. <https://doi.org/10.18203/2320-1770.ijrcog20184477>.
3. Abdelazim IA, Elezz AA. Complementary roles of hysteroscopy and saline infusion hysterosonography in uterine cavity assessment before in vitro fertilization. *Asian Pac J Reprod* 2012; 1:13-6. [https://doi.org/10.1016/s2305-0500\(13\)60040-8](https://doi.org/10.1016/s2305-0500(13)60040-8).

4. Yadav J, Manchanda S, Lokhande VS. Role of hysteroscopy in evaluation of uterine cavity abnormalities in patients of infertility: a comparative study with sonography. *Int J Med Public Health* 2024;14 <https://doi.org/10.5530/ijmedph.2024.2.33>.
5. Adenin I, Lubis HP, Halim B. Evaluation of uterine cavity abnormality using saline infusion sonohysterography before in vitro fertilization. *Open Access Maced J Med Sci* 2021; 9:917–20. <https://doi.org/10.3889/oamjms.2021.6884>.
6. Seshadri S, El-Toukhy T, Douiri A, Jayaprakasan K, Khalaf Y. Diagnostic accuracy of saline infusion sonography in the evaluation of uterine cavity abnormalities prior to assisted reproductive techniques: a systematic review and meta-analyses. *Hum Reprod Update* 2015; 21:262–74. <https://doi.org/10.1093/humupd/dmu057>.
7. Chauhan V, Singh P. Evaluation of diagnostic accuracy of saline infusion sonography with hysteroscopy in infertile women. *Trends Clin Med Sci* 2023. 98-102 <https://doi.org/10.30538/psrp-tmcs2023.si-imrv015>.
8. Tokgoz VY, Oge T, Korkmazer E, Tekin AB. The comparison of saline infusion sonography and transvaginal sonography for the intracavitary lesions in infertile women. *Ann Med Res* 2020; 27:374–0380. <https://annalsmedres.org/index.php/aomr/article/view/538>.
9. Pujar Y, Sherigar B, Patted S, Desai BR, Dhumale H. Comparative evaluation of saline infusion sonohysterography and hysteroscopy for diagnosis of uterine cavity abnormalities and tubal patency in infertility: A one-year cross-sectional study. *J SAFOG* 2010; 2:133–5. <https://doi.org/10.5005/jp-journals-10006-1081>.
10. Bingol B, Gunenc Z, Gedikbasi A, Guner H, Tasdemir S, Tiras B. Comparison of diagnostic accuracy of saline infusion sonohysterography, transvaginal sonography and hysteroscopy. *J Obstet Gynaecol* 2011; 31:54–8. <https://doi.org/10.3109/01443615.2010.532246>.
11. Ragni G, Diaferia D, Vegetti W, Colombo M, Arnoldi M, Crosignani PG. Effectiveness of sonohysterography in infertile patient work-up: A comparison with transvaginal ultrasonography and hysteroscopy. *Gynecol Obstet Invest* 2005; 59:184–8. <https://doi.org/10.1159/000084294>.
12. Kelekci S, Kaya E, Alan M, Alan Y, Bilge U, Mollamahmutoglu L. Comparison of transvaginal sonography, saline infusion sonography, and office hysteroscopy in reproductive-aged women with or without abnormal uterine bleeding. *Fertil Steril* 2005; 84:682–6. <https://doi.org/10.1016/j.fertnstert.2005.03.036>.
13. Tiwari A, Singh BK, Mishra A. A comparative study to evaluate diagnostic accuracy and correlation between saline infusion sonography, hysterosalpingography and diagnostic hysteroscopy in infertility. *Int J Reprod Contracept Obstet Gynecol* 2020; 9:669. <https://doi.org/10.18203/2320-1770.ijrcog20200356>.